

# Patent™ zirconia implant system

## A case report

Dr Sebastian Horvath, Germany

### Introduction

Growing health concerns of patients have led to an increasing demand of metal-free restorations. The same is true for dental implants. As dental professionals it is our goal to fulfil this demand of our patients in the most predictable way. When it comes to implant treatments the two most crucial aspects regarding a treatment success are the osseointegration of the implant and the prosthetic workflow. The

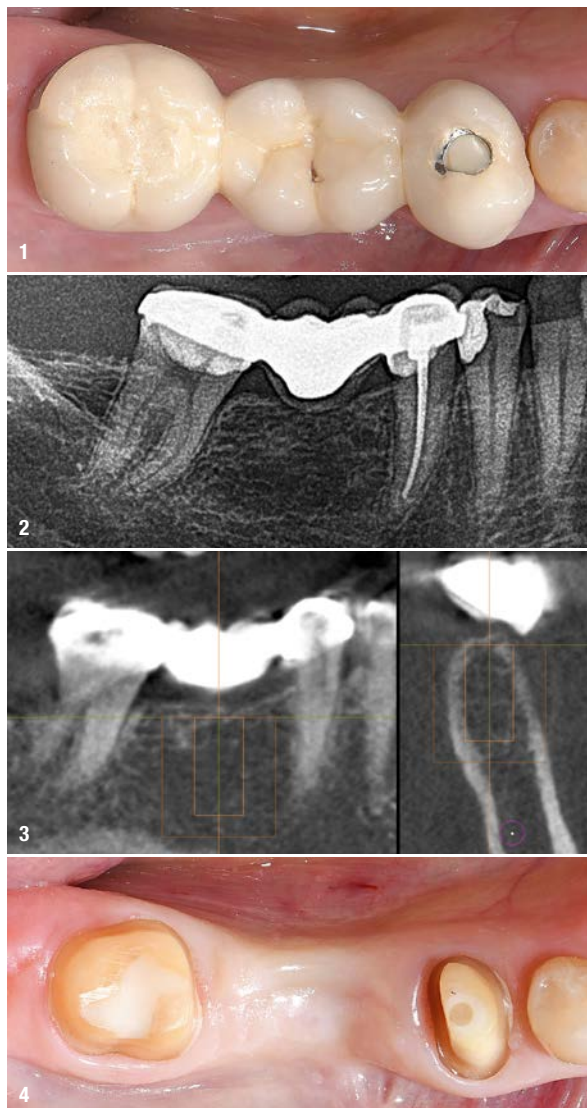
Patent™ implant system features a novel zirconia implant design with an innovative prosthetic connection. In a prospective cohort study by Becker et al. 2017, the Patent™ implant system was evaluated for posterior single tooth applications with good results. The survival rate was 95.8% after two years. A very positive soft tissue response was also reported. This is in line with what was reported by Brüll et al. 2014, in a 3-year retrospective follow-up. The following case report shows the replacement of a lower molar using the Patent™ zirconia implant system.

### Initial situation

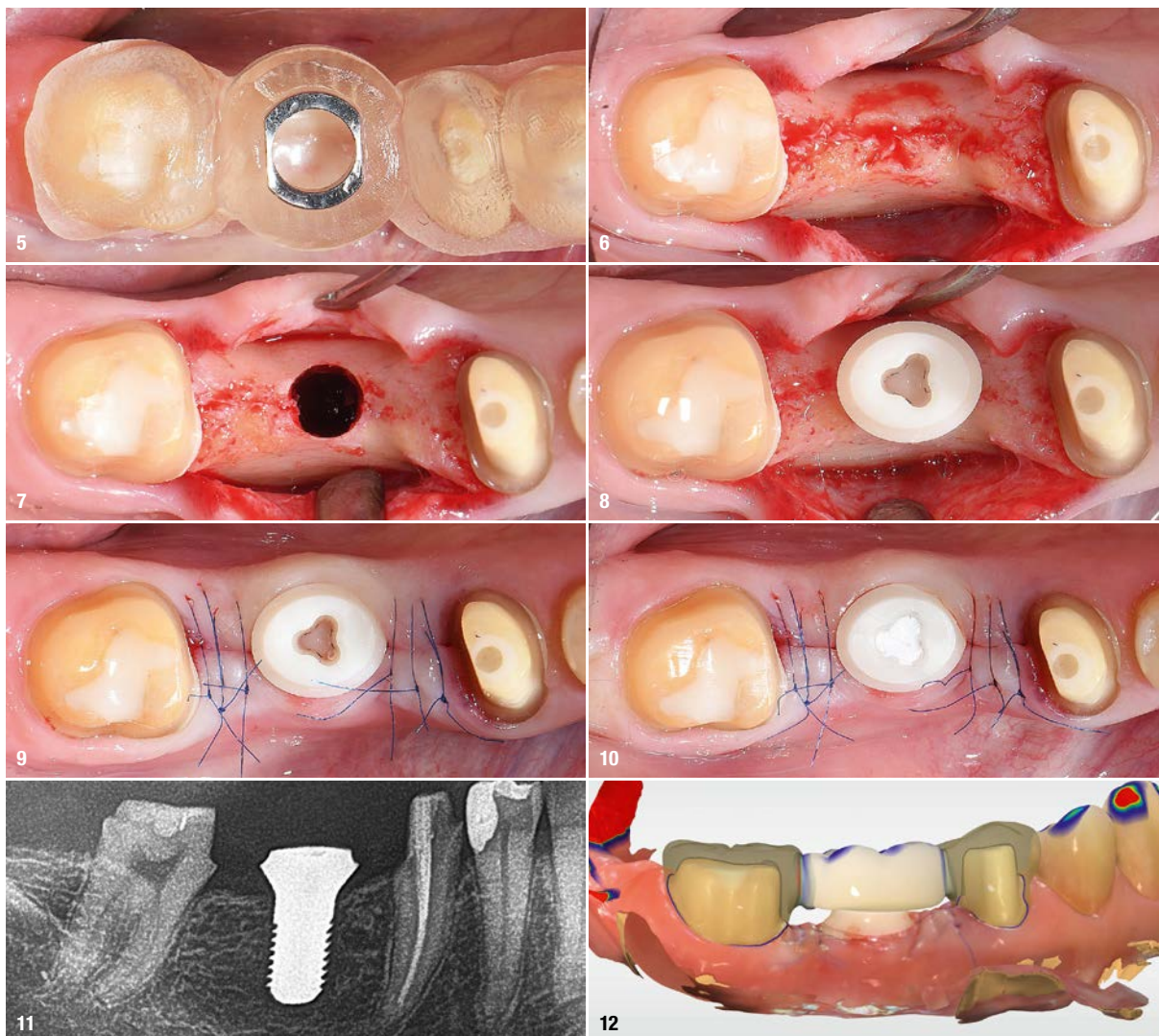
A 54-year old female patient presented at the author's office, asking for a general restoration of her teeth. As a part of this complex case the lower right quadrant was restored (Figs. 1 & 2). The treatment of this area is the subject of this case report. The patient reported that the old restoration was placed about 20 years ago after tooth #46 was lost due to endodontic complications. A few years after the placement of the restoration tooth #45 was endodontically treated through the placed restoration. Now the patient reported an increasing sensitivity on tooth #47 due to ill-fitting margins. It was planned to restore the area with two all-ceramic crowns on teeth #45 & 47, and an implant-retained restoration in site #46. The implant-retained restoration was preferred to a new fixed dental prosthesis in order to reduce the load on the endodontically treated tooth #45 and to reduce future risks by incorporating an endodontically treated tooth in a larger restoration. Initially, a CBCT was made in order to evaluate the bone volume in the edentulous areas and to evaluate existing root canal treatments.

### Pre-treatment

The CBCT revealed sufficient bone volume in site #46 to place an implant (Fig. 3). A custom implant was designed in order to get the optimal transgingival design for this in-



**Fig. 1:** Initial situation in the lower right quadrant. The patient reported about increasing sensitivity on tooth #47. **Fig. 2:** Initial radiograph showing the lower right quadrant. Note the ill-fitting margin distal on tooth #47. **Fig. 3:** A CBCT revealed sufficient bone volume in site #46 to place an implant. **Fig. 4:** Clinical situation prior to the surgery.



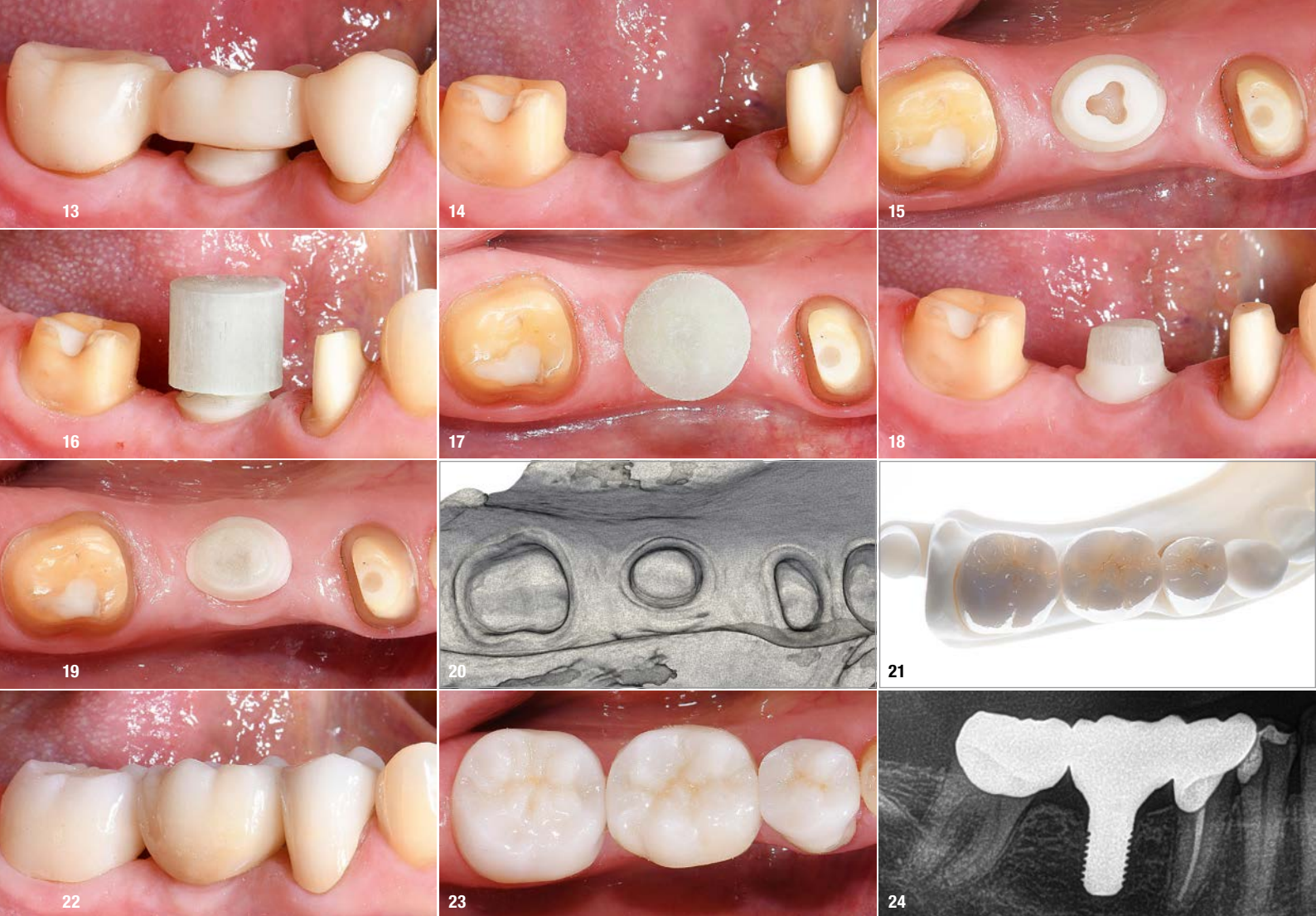**Fig. 5:** The placed surgical guide. **Fig. 6:** A full-flap was elevated to gain access to the bone. **Fig. 7:** The osteotomy was performed using the drilling protocol for hard bone. **Fig. 8:** The custom-planned zirconia implant was placed and a sufficient primary stability of 30Ncm achieved. **Fig. 9:** Wound closure. **Fig. 10:** The prosthetic connection was sealed using Teflon tape. **Fig. 11:** Radiographic evaluation of the implant position. **Fig. 12:** In the area of the newly placed implant the provisional restoration was planned as a flat pontic towards the implant with a distance of about .1 mm between the implant and the provisional restoration.

dividual case. The intrabony part of the implant had the dimensions 4.5x9mm. The old fixed dental prosthesis was removed and tooth #45 built-up with a post and core restoration. Subsequently, a digitally planned provisional restoration was fabricated and placed. The scan for the provisional restoration was further used for the fabrication of a surgical guide. For this, the scan was matched to the CBCT on the contralateral posterior teeth and the anterior teeth as they remained unchanged from the initial situation.

### Implant placement

The fit of the surgical guide was evaluated prior to the surgery (Fig. 5). Following local anaesthesia, a full-flap in site #46 was elevated to gain access to the bone (Fig. 6). The incision was performed centrally on the ridge in order to evenly space out the attached gingiva on the lingual

and buccal sides. Subsequently, a guided osteotomy was performed according to the manufacturers recommendations (Fig. 7). The drilling protocol for hard bone was used, which includes a cortical drill and a screw tap. The implant was placed and a sufficient primary stability of 30Ncm was achieved (Fig. 8). The insertion torque was measured electronically during the placement of the implant. The incision was closed and the prosthetic connection sealed using Teflon tape (Figs. 9–11). A new, digitally planned provisional restoration was fabricated (Fig. 12). In the area of the newly placed implant the provisional restoration was planned as a flat pontic towards the implant with a distance of about .1 mm between the implant and the provisional restoration. This design facilitated good cleaning in the following weeks and also ensured that the implant was unloaded during healing. Sutures were removed ten days postsurgery. Healing was uneventful.



**Fig. 13:** Clinical situation three months after implant placement. Healing was uneventful. **Fig. 14:** The implant was stable and the soft tissue presented itself as healthy. **Fig. 15:** Occlusal view. **Fig. 16:** For the prosthetic reconstruction a glass fibre post and core assembly was adhesively cemented on the implant. **Fig. 17:** The post and core assembly is pre-fabricated and tightly fits into the implant connection. **Fig. 18:** Following this build-up, the implant was prepared for a full-crown restoration just like a natural tooth. **Fig. 19:** Occlusal view. **Fig. 20:** An intra-oral scan was performed for a lab-side prosthetic workflow. **Fig. 21:** Three monolithic zirconia crowns were fabricated (Ceramics: MDT Claus-Peter Schulz). **Fig. 22:** Intra-oral view of the treatment result. **Fig. 23:** Occlusal view. **Fig. 24:** Radiographic evaluation of the treatment result.

## Prosthetic reconstruction

The prosthetic phase was commenced three months after implant placement. The provisional restoration was removed and final preparations performed on the abutment teeth. Following an uneventful healing phase, the implant was stable and the periimplant soft tissue healthy (Figs. 13–15). For the prosthetic reconstruction a glass fibre post and core assembly was adhesively cemented on the implant (Figs. 16 & 17). The post and core assembly is pre-fabricated and tightly fits into the implant connection. Following this build-up, the implant was prepared for a full-crown restoration just like a natural tooth (Figs. 18 & 19). An intra-oral scan was performed and three monolithic zirconia crowns fabricated using a lab-side workflow (Figs. 20 & 21; Ceramics: MDT Claus-Peter Schulz). The final restorations were cemented. Figures 22 to 24 show the final treatment result.



## about the author



**Dr Sebastian Horvath** specialises in aesthetic-restorative dental treatments. He works together with his wife and father in a joint practice in Jestetten, Germany. He studied dentistry at Freiburg University, where he also obtained his doctorate. He then worked at Freiburg University Hospital as a research assistant and completed a training as a listed specialist for prosthodontics. Dr Horvath teaches at the University of Pennsylvania, USA, and Düsseldorf University Hospital, Germany.

## contact

**Dr Sebastian Horvath**  
 Bahnhofstraße 24  
 79798 Jestetten, Germany  
 Phone: +49 7745 7211  
 www.drhorvath.de

